

## Huge Bladder Diverticulum Masquerading as Ovarian Tumour in a Postmenopausal Woman: A Case Report at a Private Facility in Akure

**Bamidele Jimoh Folarin<sup>1,2,5</sup>, Olurotimi Sunday Ogundiniyi<sup>1,3</sup>, \*Theresa Azonima Irinyenikan<sup>1,2</sup>, Evelyn Salewa Osho<sup>1,4</sup>**

*1Faculty of Clinical Sciences, University of Medical Sciences, Ondo city, Ondo State, Nigeria.*

*2Department of Obstetrics and Gynaecology, University of Medical Sciences Teaching Hospital Complex, Akure, Ondo State, Nigeria.*

*3Urology Unit, Department of Surgery, University of Medical Sciences Teaching Hospital Complex, Ondo, Ondo State, Nigeria.*

*4Department of Radiology, University of Medical Sciences Teaching Hospital Complex, Ondo, Ondo State, Nigeria.*

*5Medical Director, FOBAM Specialist Hospital, NEPA, Akure, Ondo State, Nigeria*

\*Corresponding author: **Bamidele Jimoh Folarin**

©2024 the Author(s). This is an open access article distributed under the terms of the Creative Commons Attribution License (<http://creativecommons.org/licenses/by/4.0>)

**Abstract:** Background: Huge bladder diverticulum can mimick ovarian tumour most especially in postmenopausal women thus leading to a presentation at a gynaecological clinic. Case Reported: We report a case of a 58-year old P7+0 (6Alive) postmenopausal woman who presented at the gynaecological unit of a private facility in Akure, Ondo State with progressive abdominal swelling of 5years duration. She was earlier seen by a physician who requested for an Abdominal CT scan. She then presented with the report which did not comment on the ovaries. Considering the peak incidence of invasive epithelial ovarian cancer which usually occurs at 50-60 years of age and the small risk of false negative result in imaging study, an abdomino-pelvic ultrasound was ordered which suggested a huge bladder diverticulum. The case was co- managed with the gynaecological and urology team and she subsequently had exploratory laparotomy and open diverticulectomy with a successful outcome. Conclusion: Huge bladder diverticulum in women can present to gynaecological clinics most especially in the postmenopausal period, a high index of suspicion coupled with necessary investigations will be required to effectively manage.

**Keywords:** Huge Bladder Diverticulum, Postmenopausal, Private Facility, Successful Outcome.

### INTRODUCTION

Bladder diverticulum is a herniation of mucosa lacking a muscle layer which results in a loss of contractility and urine stasis in the diverticulum [1]. Most cases are asymptomatic and only discovered incidentally on imaging study. It can be congenital or acquired, benign or malignant manifesting as ovarian tumour [2,3]. They are rare in women and most often described in men[4]. They are often cystic and their cystic nature can simulate other cystic masses of the abdominal cavity such as oophoritic cyst, ovarian serous tumour, appendiceal mucocele and appendix mucinous tumour [3,5,6]. Although they are usually small and asymptomatic; some may cause lower urinary tract symptoms (LUTS) just like ovarian tumour, hematuria, stone formation or malignant change [7,8,9].

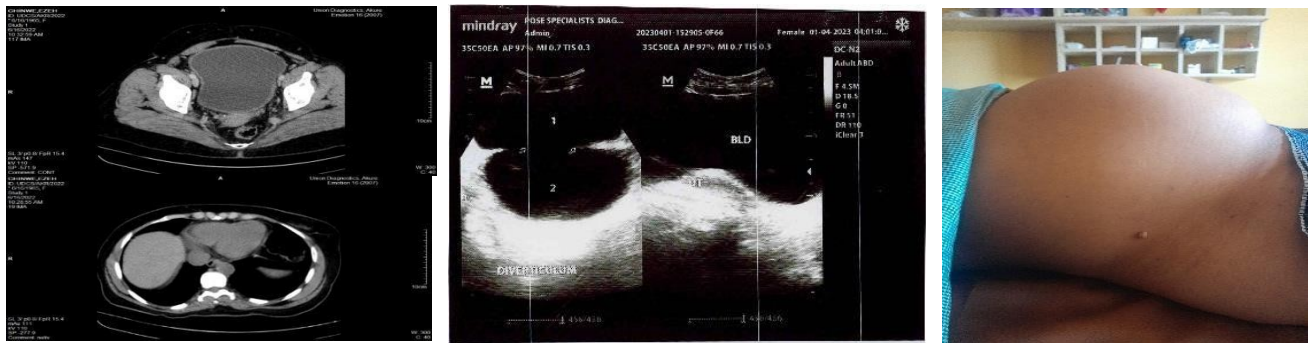
### CASE REPORT

This was a case of a 58-year old P<sup>+0</sup>(6A) postmenopausal woman who presented to FOBAM Specialist Hospital NEPA, Akure on the 20<sup>th</sup> of April 2023 with complaints of abdominal distension of 5 years duration and frequent micturition with occasional straining to pass urine. There was no associated abdominal pain, no cough, no weight loss, no hematuria, no dysuria and no postmenopausal bleeding. She had an abdominal CT scan prior to presentation which revealed a cystic mass arising from the pelvis into the abdomen measuring about 20cm by 10cm (A.P diam) and cannot be differentiated from the distended bladder. The uterus was posterior to the mass and compressed by the mass. There was no comment on both

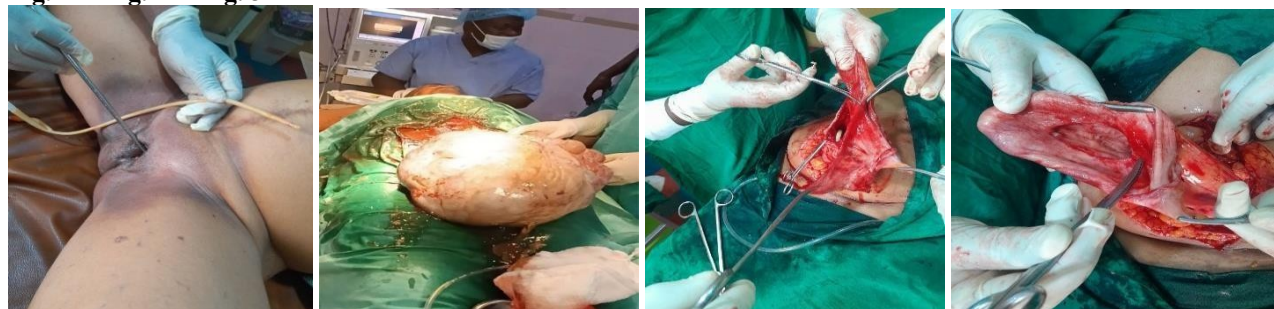*How to cite: Bahtiar et al Huge Bladder Diverticulum Masquerading as Ovarian Tumour in a Postmenopausal Woman: A Case Report at a Private Facility in Akure." J Mod Med Sci, 1, no. 1 (2025): 29-32.*

ovaries [Figure 1]. Pelvic USS was then ordered which revealed a huge cystic abdomino-pelvic mass connected to the urinary bladder. No mass or collection was noted in the adnexa bilaterally [Figure 2]. A urine culture done showed mixed growth of proteus vulgaris and candida albicans sensitive to Ciprofloxacin. Electrolytes, urea and creatinine were normal, Hepatitis B surface Antigen and retroviral screening were non-reactive. FBC-PCV was 30%, WBC-  $4.1 \times 10^3/L$ , PLT- $179 \times 10^9/L$ . She had a myomectomy done in 1993 and a Caesarean section done in 1995.

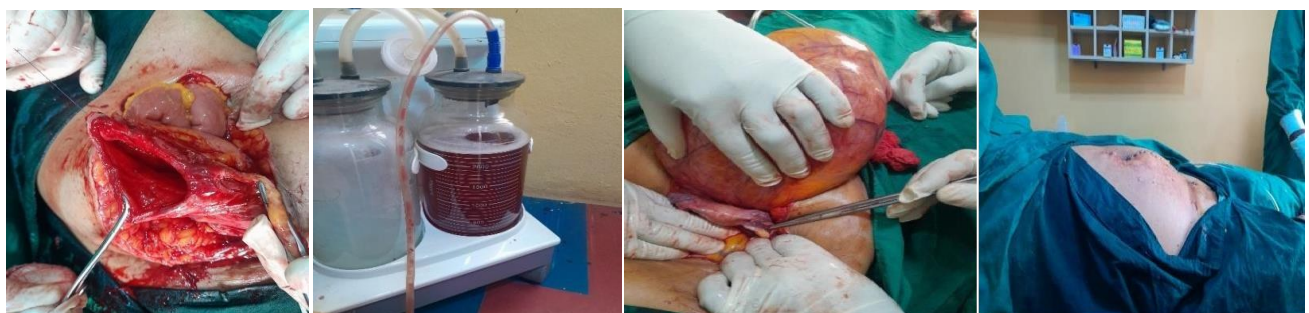Examination revealed a middle-aged woman with an abdomino- pelvic mass of about 32 weeks size soft and fluctuant in consistency [Figure 3]. Patient had tight but dilatable urethral stricture for which bougienage was done [Figure 4]. On the 22<sup>nd</sup> of April 2023, she had exploratory laparotomy with intravesical diverticulectomy and dissection of the diverticulum [Figures 5a-d] and about 2.3L of urine was drained [Figure 6]. Other intra-operative findings were thickened bladder wall, grossly normal kidneys on palpation and no hydronephrosis, atrophic uterus and ovaries and normal adnexae posterior to the diverticulum [Figure7]. There was no renal stone. She was managed post- operatively with parenteral antibiotics and urethral catheter was removed after 14 days, bladder training was commenced and urinary symptoms abated. Histology showed bladder mucosa lined by urothelium with fibrous wall and thin smooth muscle with areas of extravasation of blood. Also seen were mononuclear inflammatory cells, granulation tissue formation, areas of erosion, cystic glandularis and non-keratinizing squamous metaplasia in keeping with bladder diverticulum. She was discharged home on the 16<sup>th</sup> day post-operatively [8<sup>th</sup> May 2023] in a stable condition [Figure 8].



**Fig. 1 Fig. 2 Fig. 3**



**Fig. 4 Fig. 5a Fig. 5b Fig. 5c**



How to cite: Bahtiar et al Huge Bladder Diverticulum Masquerading as Ovarian Tumour in a Postmenopausal Woman: A Case Report at a Private Facility in Akure." J Mod Med Sci, 1, no. 1 (2025): 29-32.

## Fig. 5d Fig. 6 Fig. 7 Fig. 8

### Discussion

We presented a 58-year old P7<sup>+0</sup> (6A) postmenopausal women who were managed as a case of huge bladder diverticulum which mimicked ovarian tumour because of the massive size. She presented with complaints of abdominal distension with LUTS. Diverticulum can be detected by ultrasonography, CT and MRI [3]. In this case, CT scan of the abdomen revealed a huge bladder diverticulum but was silent on the ovaries (adnexia), this is not surprising as it is not routinely used in the evaluation of adnexal mass[10]; the pelvic ultrasound was used as a complementary tool to detect the adnexia since it remains the most important tool in the evaluation of adnexal mass[10]. This is very important in this case because the patient presented with a distended abdomen that was cystic in consistency. A mucinous ovarian tumour has a similar presentation and may reach enormous size, filling the entire abdominal cavity [11]. There were also LUTS in this patient and both diverticulum and ovarian tumour can present with LUTS [7,8].

A diagnosis of huge bladder diverticulum was finally made. A diverticulum can be congenital or acquired with the congenital one occurring in 1.7 % of children [3] and bear no risk of malignancy while the acquired one has the risk of malignancy and often precipitated by lower urinary tract obstruction [13] as seen in this case which was dilated. The features of malignancy were ruled out by the aforementioned history. She had surgery and the resected specimen was sent for histology to rule out the possibility of malignancy most especially because of the late diagnosis and some have been reported to be associated with early invasion of cancer which could result from the lack of muscular fibres of diverticulum [14].

The surgical options in the management of cases of bladder diverticulum include open diverticulum (intra or extravesical) and laparoscopic approach [15]. In this case, we preferred open diverticulectomy to enable us look out for the presence of renal stones in the bladder and there was none. This patient had urethral stricture that could have been responsible for the huge bladder diverticulum.

### Conclusion

We presented a case of an abdominal swelling in a postmenopausal woman due to bladder diverticulum that mimicked an ovarian tumour and the patient was jointly managed by the gynaecological and the urology team with a successful outcome. Cases presenting to the gynaecological clinic especially in the postmenopausal period require a high index of suspicion and the necessary investigations to guide diagnosis and management.

### References

1. Garat JM, Angerri O, Caffaratti J et al. Primary congenital bladder diverticula in children. *Urology* 2007; 70 (5): 984-988.
2. Sheldon CA, Essig KA. Congenital bladder diverticulum causing bladder outlet obstruction: case report and review of the literature. *Pediatric Surg Int.* 1994; 9: 141- 143.
3. ShuangHong Jiang, QuanRen, Xianfei Wang et al. A huge bladder diverticulum in an elderly: A case report. *SAGE open medical case reports.* 2020; 8:1-4.
4. Levard G, Aigrain Y, Ferkadji L, Elghoneimi A, Pichon J, Boureau M. Urinary bladder diverticula and the Ehlers-Danlos syndrome in Children. *J Pediatr Surg.* 1989; 24: 1184- 1186.
5. Okumurra T, Muronosono E, Tsubuku M, et al. Anaplastic carcinoma in ovarian malignancy. *J Ovarian Res* 2018; 11:77.
6. Dellaportas D, Vlahos N, polymeneas G et al. Collision tumor of the appendix: Mucinous cystadenoma and carcinoid. A case report. *Chirurgia (Bucur)* 2014; 109(6): 843-845.
7. Abouzahr, Chalhoub K, Ollaik K. et al. Congenital bladder diverticulum in adults: A case report and review of the literature. *Case rep Urol* 2018; 2018: 9748926.
8. Kwawukume EY, Emuveyan EE. In *Comprehensive Gynaecology In the Tropics*. 2005 Edition and published by the Graphic Packaging Limited pg. 453.
9. Shar B, Rodriguez R, Krasnokutsky S et al. Tumour in a giant bladder diverticulum: A case report and review of literature. *Int Urol Nephrol* 1997; 29(2): 173-179.
10. John Studd. In *Progress in Obstetrics and Gynaecology*. 2006, Volume 17 and published by Churchill Livingstone.

pg 310.

11. Jonathan S. Berek. In Berek and Novak's Gynaecology 2007 edition and published by Lippincott and wilkins .pg 1462.
12. Alexander RE, Kum JB and Idrees M. Bladder diverticulum: Clinicopathologic spectrum in pediatric patients .Pediatr .Dev Pathol 2012; 15(4): 281-285.
13. Silberman M, Jeanmonod R. Bladder diverticulitis: A case report. Case Rep Emerg Med. 2011; 2011: 303498.
14. Moussa and Abou chakra M. Urothelial carcinoma arising from a bladder diverticulum containing multiple stones: A case report .Urol Case Rep 2018; 20:80-82.
15. Vaddi S, Pogula V, Devraj R et al. Congenital bladder diverticulum- A rare adult presentation. J Surg Case Rep 2011; 2011:8.