

## Neoterics Preparation of PLGA Loaded Nedaplatin Nanoparticles by Various Data Analysis

*Senkuttuvan Ilanchit Chennai[a], Dr. Kathiresan Suresh[a]\*, Dr. Palanivel Venkatesan[b], Dr. Nagappan Kannappan[b], Dr. Muthusamy Rajasekar[c], Abulkalam Asath Nihal Ahamed[a], Ravichandran Pugazhendhi[a]*

*[a] S. Ilanchit Chennai, Dr. K. Suresh, A. Nihal Ahamed, R. Pugazhendhi, Department of Biochemistry and Biotechnology, Annamalai University, Annamalai Nagar, Chidambaram, Tamil Nadu 608002, India.*

*[b] Dr. P. Venkatesan, Dr. N. Kannappan, Department of Pharmacy, Annamalai university, Annamalai University, Annamalai Nagar, Chidambaram, Tamil Nadu, 608002, India*

*[c] Dr. Muthusamy Rajasekar, Central Research Laboratory for Biomedical Research, Vinayaka Missions' Kirupananda Variyar Medical College and Hospitals, Salem 636308 India.*

*E-mail: suraj\_cks@yahoo.co.in\*, ilanchitchenni30@gmail.com venkatesan1978@gmail.com, kannappanpharmacy@gmail.com, nihalahamed2013@gmail.com, pugazhmyr@gmail.com*

*\* Corresponding author: Dr. Kathiresan Suresh, Associate Professor, Department of Biochemistry and Biotechnology, Annamalai University, Annamalainagar – 608 002, Tamilnadu, India  
E.mail: suraj\_cks@yahoo.co.in*

©2024 the Author(s). This is an open access article distributed under the terms of the Creative Commons Attribution License (<http://creativecommons.org/licenses/by/4.0>)

**Abstract:** Poly-(D, L-lactic-co-glycolic) acid (PLGA)-loaded nedaplatin nanoparticles (PLGA-NDP) were prepared. The details of the preparation and characterisation of PLGA-loaded Nedaplatin nanoparticles formed and optimised by the double emulsion technique and Box–Behnken design with poly-(D, L-lactic-co-glycolic) acid as a polymer and polyvinyl alcohol (PVA) as surfactant agents were investigated. The morphology and elemental distribution, physical state, internal structure, encapsulation efficiency, and release profile were examined through sequential tactics such as Scanning Electron Microscopy-Energy Dispersive X-ray, Dynamic light scattering, Thermogravimetric analysis-Differential thermal analysis, Fourier-Transform Infrared Spectroscopy, UV-VIS spectroscopy, and in-vitro drug release study, respectively. Four factors at four levels were used in the Box-Behnken design to calculate the central point. The interaction between these factors significantly enhanced the results. The response of the optimised condition provided an accurate prediction, and the experiment was conducted further. The design was validated, and satisfactory agreement was observed between the predicted and experimental values. The obtained results provide evidence of a new geometric construction of PLGA-loaded nedaplatin nanoparticles with enhanced efficiency when compared to the reported research articles related to nedaplatin in cancer studies. Therefore, these findings and techniques are useful for the preparation of NPs.

**Keywords:** • Drug Delivery Systems, • Double Emulsion Technique; • Poly-(D, L-lactic-co-glycolic) acid; • Nedaplatin; • Box-Behnken design.

### INTRODUCTION

Investigations in modern drug research have highlighted the importance of biodegradable polymer nanoparticles as drug delivery systems to enhance bioavailability while maintaining therapeutic efficacy [1]. Nanoparticles are integral in nanotechnology, especially for drug delivery. In cancer treatment, nanoparticles serve as anticancer agent carriers, using passive and active targeting at the tumour site [2,3]. Passive targeting relies on the accumulation of therapeutic agents, despite differences between carcinomas and normal tissues. Rezvantlab et al. (2018), Danaei et al. (2018), and Yetisgin et al. (2020) reported that vascular and lymphatic dysfunction results in increased permeability and retention effect (EPR), aiding transportation and retention of therapeutic nanoparticles. Nanoparticle uptake into the targeted or mucosal barrier is limited [3–5]. Nanoparticle properties, including size, shape, and surface charge, affect the EPR effect,

influencing circulation duration, penetration rate, and cellular internalisation. Physicochemical properties also affect nanoparticle extravasation and accumulation [6]. Polymer nanoparticles are optimal for sophisticated drug delivery systems, aiming to improve therapeutic and rehabilitative efficacy. Polymeric nanoparticles with surfactants enhance drug delivery stability, controlled release, particle size, site targeting, bioavailability, biocompatibility, physical properties, and preservation of pharmaceutical molecules from threats and environmental degradation [7].

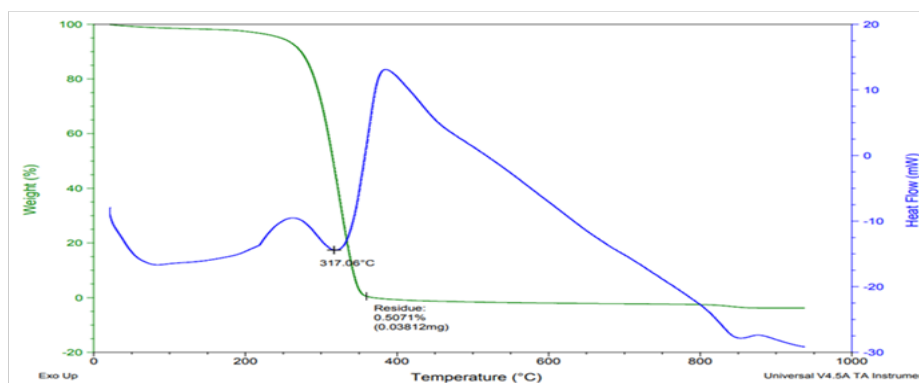
An effective method is the response surface methodology (RSM), which includes central composite design (CCD), Box–Behnken design (BBD), and D-optimal design. BBD was used to optimise the formulation of nanoparticles to minimise particle size and maximise yield, encapsulation efficiency, and drug release. The BBD design provides a superior illustration of intervariable reactions and optimises these factors with reduced time and minimal experimental effort [8–10]. Nedaplatin (cis-diamine-glycopolatinum) is a derivative of cisplatin, first reported in Japan in 1983. Its antineoplastic potency treats various tumours, including head and neck, oesophageal, uterine, ovarian, and lung cancers [11]. In clinical studies in Japan, Nedaplatin has shown remarkable therapeutic efficacy against head and neck, lung, and cervical cancers, with lower renal and gastrointestinal toxicity compared to Cisplatin [12,13].

Poly-(D, L-lactic-co-glycolic) acid (PLGA) polymer was selected for its superior drug carrier properties, including encapsulation efficiency, reduced adverse effects, and prevention of drug degradation. Cancer development and progression can be influenced by factors such as disruption of tumour suppressor genes, irregular cellular differentiation, and malfunctioning apoptosis caused by excessive proliferation[14,15]. While nanoformulation has advanced significantly, various research areas require attention, including precise manipulation of nanostructures, scalable synthesis techniques, enhancement of functionalisation methods, environmental sustainability, and data-centric synthesis strategies. In this study, the properties of PLGA encapsulating nedaplatin were examined to reach the therapeutic efficacy.

## MATERIALS AND METHODS

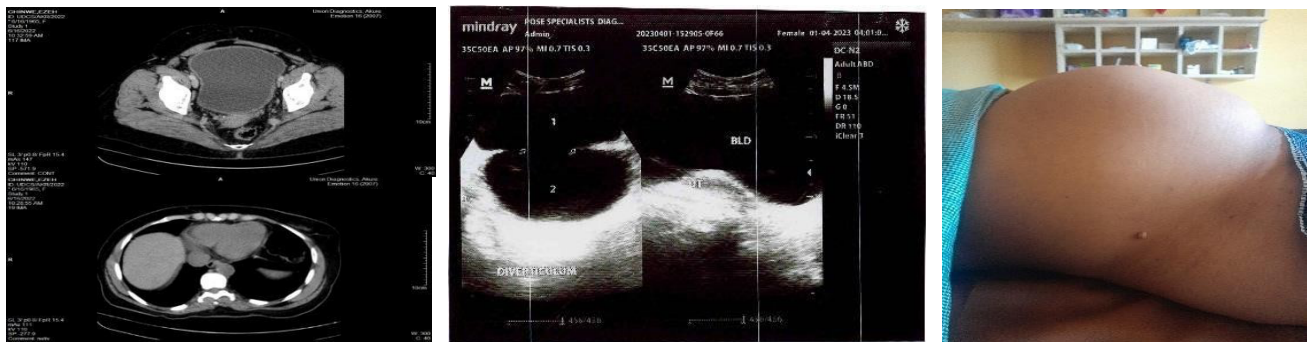
Poly-(D, L-lactic-co-glycolic) acid (PLGA) [Nomisma Healthen Pvt. Ltd], cis-di ammine(glycolate) platinum II (Nedaplatin) [Sigma Aldrich], polyvinyl alcohol (PVA) [MP Biomedical], dichloromethane [MP Biomedical], phosphate-buffered saline (PBS) [Lonza], and dialysis membranes [HI media] were purchased.

**Fig. 6 Image of Thermal Analysis (TG/DTA) curve.**

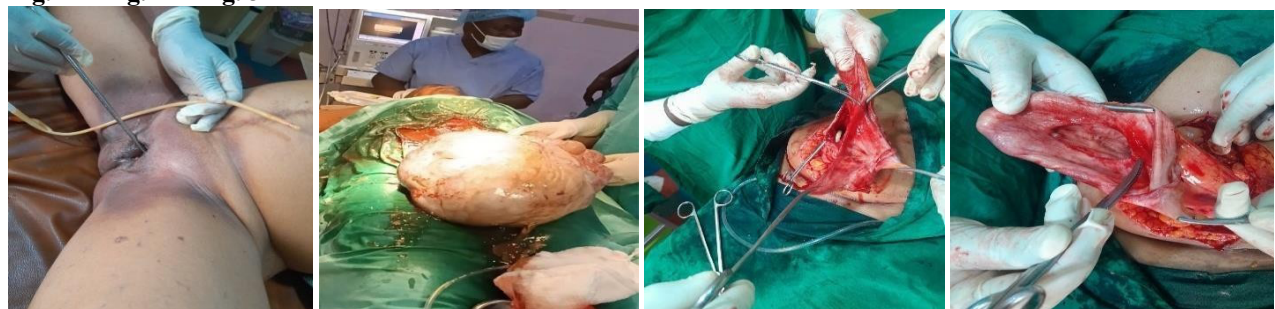

ovaries [Figure 1]. Pelvic USS was then ordered which revealed a huge cystic abdomino-pelvic mass connected to the urinary bladder. No mass or collection was noted in the adnexa bilaterally [Figure 2]. A urine culture done showed mixed growth of proteus vulgaris and candida albicans sensitive to Ciprofloxacin. Electrolytes, urea and creatinine were normal, Hepatitis B surface Antigen and retroviral screening were non-reactive. FBC-PCV was 30%, WBC-  $4.1 \times 10^3/L$ , PLT- $179 \times 10^9/L$ . She had a myomectomy done in 1993 and a Caesarean section done in 1995.

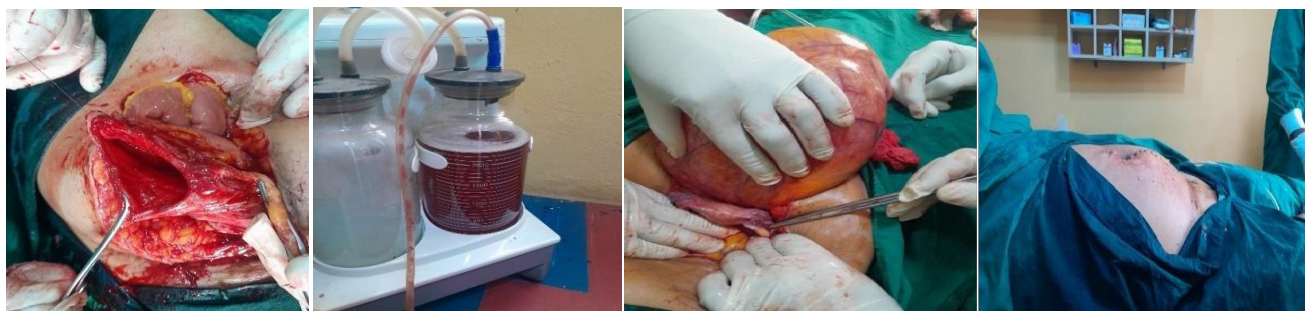Examination revealed a middle-aged woman with an abdomino- pelvic mass of about 32 weeks size soft and fluctuant in consistency [Figure 3]. Patient had tight but dilatable urethral stricture for which bougienage was done [Figure 4]. On the 22<sup>nd</sup> of April 2023, she had exploratory laparotomy with intravesical diverticulectomy and dissection of the diverticulum [Figures 5a-d] and about 2.3L of urine was drained [Figure 6]. Other intra-operative findings were thickened bladder wall, grossly normal kidneys on palpation and no hydronephrosis, atrophic uterus and ovaries and normal adnexae posterior to the diverticulum [Figure7]. There was no renal stone. She was managed post- operatively with parenteral antibiotics and urethral catheter was removed after 14 days, bladder training was commenced and urinary symptoms abated. Histology showed bladder mucosa lined by urothelium with fibrous wall and thin smooth muscle with areas of extravasation of blood. Also seen were mononuclear inflammatory cells, granulation tissue formation, areas of erosion, cystic glandularis and non-keratinizing squamous metaplasia in keeping with bladder diverticulum. She was discharged home on the 16<sup>th</sup> day post-operatively [8<sup>th</sup> May 2023] in a stable condition [Figure 8].



**Fig. 1 Fig. 2 Fig. 3**



**Fig. 4 Fig. 5a Fig. 5b Fig. 5c**



How to cite: Bahtiar et al Huge Bladder Diverticulum Masquerading as Ovarian Tumour in a Postmenopausal Woman: A Case Report at a Private Facility in Akure." *J Mod Med Sci*, 1, no. 1 (2025): 29-32.

Fig. 5d Fig. 6 Fig. 7 Fig. 8

## Discussion

We presented a 58-year old P7<sup>+0</sup> (6A) postmenopausal women who were managed as a case of huge bladder diverticulum which mimicked ovarian tumour because of the massive size. She presented with complaints of abdominal distension with LUTS. Diverticulum can be detected by ultrasonography, CT and MRI [3]. In this case, CT scan of the abdomen revealed a huge bladder diverticulum but was silent on the ovaries (adnexia), this is not surprising as it is not routinely used in the evaluation of adnexal mass[10]; the pelvic ultrasound was used as a complementary tool to detect the adnexia since it remains the most important tool in the evaluation of adnexal mass[10]. This is very important in this case because the patient presented with a distended abdomen that was cystic in consistency. A mucinous ovarian tumour has a similar presentation and may reach enormous size, filling the entire abdominal cavity [11]. There were also LUTS in this patient and both diverticulum and ovarian tumour can present with LUTS [7,8].

A diagnosis of huge bladder diverticulum was finally made. A diverticulum can be congenital or acquired with the congenital one occurring in 1.7 % of children [3] and bear no risk of malignancy while the acquired one has the risk of malignancy and often precipitated by lower urinary tract obstruction [13] as seen in this case which was dilated. The features of malignancy were ruled out by the aforementioned history. She had surgery and the resected specimen was sent for histology to rule out the possibility of malignancy most especially because of the late diagnosis and some have been reported to be associated with early invasion of cancer which could result from the lack of muscular fibres of diverticulum [14].

The surgical options in the management of cases of bladder diverticulum include open diverticulum (intra or extravesical) and laparoscopic approach [15]. In this case, we preferred open diverticulectomy to enable us look out for the presence of renal stones in the bladder and there was none. This patient had urethral stricture that could have been responsible for the huge bladder diverticulum.

## Conclusion

We presented a case of an abdominal swelling in a postmenopausal woman due to bladder diverticulum that mimicked an ovarian tumour and the patient was jointly managed by the gynaecological and the urology team with a successful outcome. Cases presenting to the gynaecological clinic especially in the postmenopausal period require a high index of suspicion and the necessary investigations to guide diagnosis and management.

## References

1. Garat JM, Angerri O, Caffaratti J et al. Primary congenital bladder diverticula in children. *Urology* 2007; 70 (5): 984-988.
2. Sheldon CA, Essig KA. Congenital bladder diverticulum causing bladder outlet obstruction: case report and review of the literature. *Pediatric Surg Int.* 1994; 9: 141- 143.
3. ShuangHong Jiang, QuanRen, Xianfei Wang et al. A huge bladder diverticulum in an elderly: A case report. *SAGE open medical case reports.* 2020; 8:1-4.
4. Levard G, Aigrain Y, Ferkadji L, Elghoneimi A, Pichon J, Boureau M. Urinary bladder diverticula and the Ehlers-Danlos syndrome in Children. *J Pediatr Surg.* 1989; 24: 1184- 1186.
5. Okumurra T, Muronosono E, Tsubuku M, et al. Anaplastic carcinoma in ovarian malignancy. *J Ovarian Res* 2018; 11:77.
6. Dellaportas D, Vlahos N, polymeneas G et al. Collision tumor of the appendix: Mucinous cystadenoma and carcinoid. A case report. *Chirurgia (Bucur)* 2014; 109(6): 843-845.
7. Abouzahr, Chalhoub K, Ollaik K. et al. Congenital bladder diverticulum in adults: A case report and review of the literature. *Case rep Urol* 2018; 2018: 9748926.
8. Kwawukume EY, Emuveyan EE. In *Comprehensive Gynaecology In the Tropics*. 2005 Edition and published by the Graphic Packaging Limited pg. 453.
9. Shar B, Rodriguez R, Krasnokutsky S et al. Tumour in a giant bladder diverticulum: A case report and review of literature. *Int Urol Nephrol* 1997; 29(2): 173-179.
10. John Studd. In *Progress in Obstetrics and Gynaecology*. 2006, Volume 17 and published by Churchill Livingstone.

pg 310.

11. Jonathan S. Berek. In Berek and Novak's Gynaecology 2007 edition and published by Lippincott and wilkins .pg 1462.
12. Alexander RE, Kum JB and Idrees M. Bladder diverticulum: Clinicopathologic spectrum in pediatric patients .Pediatr .Dev Pathol 2012; 15(4): 281-285.
13. Silberman M, Jeanmonod R. Bladder diverticulitis: A case report. Case Rep Emerg Med. 2011; 2011: 303498.
14. Moussa and Abou chakra M. Urothelial carcinoma arising from a bladder diverticulum containing multiple stones: A case report .Urol Case Rep 2018; 20:80-82.
15. Vaddi S, Pogula V, Devraj R et al. Congenital bladder diverticulum- A rare adult presentation. J Surg Case Rep 2011; 2011:8.